Interim Evaluation of Phase II Clinical Trial: Lacripep Ophthalmic Solution versus Placebo for Corneal Wound Healing after PRK

R.K. Sia[1,2*], D.S. Ryan[1,2*], K.E. Paulett[1,2*], A.C. Hogan[1,2*], B.G. Kuhar[2], G.W. Laurie[3], M.G. Odrich[3], Z.P. Skurski[2]

[1]*Henry M. Jackson Foundation for the Advancement of Military Medicine, Inc., Bethesda, MD, USA*

[2]*Warfighter Refractive Eye Surgery Program and Research Center at Fort Belvoir, Fort Belvoir, VA, USA*

[3]*TearSolutions, Inc. Charlottesville, VA, USA*

Abstract ID: MHSRS-26-3709

Learning Objectives

A. Discuss Lacripep, a novel peptide-based topical therapeutic, for potential treatment of superficial corneal injuries

B. Describe the use of surface ablation surgery as a controlled superficial injury model in a corneal wound healing study

C. Analyze interim and early findings of a contralateral eye study comparing Lacripep versus placebo as an adjunct to corneal healing after photorefractive keratectomy (PRK)

Introduction and Study Purpose

Image by Jeff Romano

Figure 1. Lacritin protein structure model.

Lacripep (TearSolutions, Inc.), a first-in-class topical synthetic peptide, is an emerging therapeutic with the potential to facilitate wound healing after a superficial corneal injury. It is derived from a human tear protein called Lacritin, which has been shown to promote regenerative corneal repair and restore ocular surface homeostasis in the presence of inflammation.[1-4]

Lacripep is a promising treatment option that could hasten recovery and expedite return to duty in corneal wounds commonly encountered in the military patient population, whether from trauma[5] or post-refractive surgery, such as photorefractive keratectomy (PRK).

Rather than attempting to initially investigate combat trauma-related eye injuries, an endeavor wrought with confounding variables, the purpose of this study is *to determine the effectiveness of Lacripep in promoting healing using corneal wound created during PRK as a standardized model*.

Methods

This is a phase 2, single center, non-randomized, single-masked, placebo-controlled, contralateral eye clinical trial of 45 participants (of the planned 88) undergoing bilateral PRK for myopia with or without astigmatism (Clinicaltrials.gov registration no.: NCT06854393).

PRK surgery: A standard **9-mm epithelial defect** was created using an Amoils rotary brush (Innova Inc.) followed by photoablation with the Wavelight Allegretto EX500 excimer laser (Alcon Surgical). Bandage contact lenses (BCL) were applied to both eyes immediately after treatment.

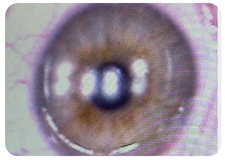

Image used with patient's permission.

Figure 2. A 9-mm epithelial defect created during PRK.

Postop medication regimen: Standard topical postop medications included moxifloxacin 0.5% eyedrops 4 times a day for 1 week, fluorometholone 0.1% eyedrops 4 times a day for 4 weeks then taper over the next 6 weeks, carboxymethylcellulose 0.5% every 30 minutes and, after BCL removal, sodium chloride 5% ointment at bedtime. Additionally, active study medication (**Lacripep eyedrops**) was applied to one assigned eye (LAC) and **placebo eyedrops** to the fellow eye (CTRL) intraoperatively and **3 times a day for 3 weeks**. Participants were followed on day 1, 4 and 7 after PRK for early postoperative clinical assessment.

Healing rates were determined by measuring central epithelial thickness (CET) over time using optical coherence tomography (OCT). Paired t-tests and repeated measures analysis of variance were performed to compare LAC versus CTRL.

Table 1. Baseline characteristics	LAC (n=45 eyes)	CTRL (n=45 eyes)	P-value
Age (years)	29.2 ±5.7		-
Sex (n male, %)	28, 62%		
Manifest Sphere (diopters, D)	-2.00 ±0.72	-2.04 ±0.82	0.525
Manifest Cylinder (D)	-0.51 ±0.41	-0.44 ±0.40	0.194
Manifest Spherical Equivalent (D)	-2.25 ±0.75	-2.26 ±0.81	0.863
Uncorrected Distance Visual Acuity (logMAR, Snellen equivalent)	0.64 ±0.26 20/80 -2	0.64 ±0.26 20/80 -2	0.975
Corrected Distance Visual Acuity (logMAR, Snellen equivalent)	-0.13 ±0.06 20/16 +1	-0.14 ±0.07 20/16 +1	0.290

Results

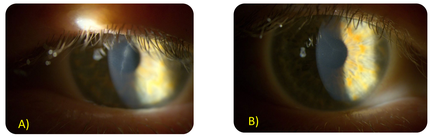

Image used with patient's permission.

Figure 3. Representative image of A) LAC and B) CTRL at POD4.

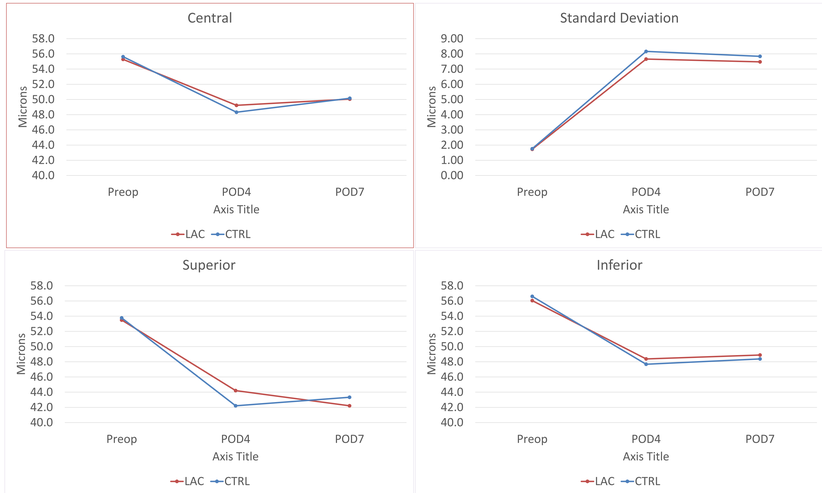

Figure 4. Corneal Epithelial Thickness by OCT in the early postoperative period.

- At POD4, the mean change in CET from baseline was -6.05µm ±8.9 in the LAC and -7.30µm ±7.21 in the CTRL (p=0.453).
- By POD 7, CET recovered with mean change -5.23µm ±5.2 in the LAC and -5.43µm ±5.1 in the CTRL and (p=0.838).

Table 2. Corneal Epithelial Healing	LAC	CTRL	P-value
Epithelial defect area at POD1 (mm^2)	22.3 ±9.6	23.0 ±8.8	0.567
Complete re-epithelialization (n eyes, %)	43, 97.7%	44, 100%	0.999
Early healing rate*			
Baseline preop to POD4 (µm/day) **	-1.51 ±2.2	-1.83 ±1.8	0.453
% Recovery rate	89.3% ±15.9	87.1% ±12.6	0.459
Late remodeling rate*			
POD4 to POD7 (µm/day) **	0.27 ±3.4	0.61 ±2.6	0.593
Overall healing rate*			
Baseline preop to POD7 (µm/day) **	-1.31 ±1.31	-1.36 ±1.27	0.838
% Recovery rate	90.6% ±9.4	90.5% ±9.0	0.942

*Based on central epithelial thickness on OCT. **healing rates closer to zero represent superior recovery (smaller epithelial thickness deficit). POD = postoperative day.

Results (continued)

Table 3. Early Clinical Outcomes	LAC	CTRL	P-value
Uncorrected distance Visual Acuity 20/20 or better (n eyes, %)			
POD1 (with BCL)	8, 18.2%	9, 20%	0.999
POD4 (with BCL)	15, 36.6%	12, 29.3%	0.639
POD4 (without BCL)	15, 34.9%	14, 32.6%	0.999
POD7 (without BCL)	27, 61.4%	28, 63.6%	0.999
Significant Corneal Haze (Grade >1; n eyes, %)			
POD1	0%	0%	-
POD4	1, 2.3%*	1, 2.3%*	0.999
POD7	0%	0%	-

*From the same participant. BCL = bandage contact lens; POD = postoperative day

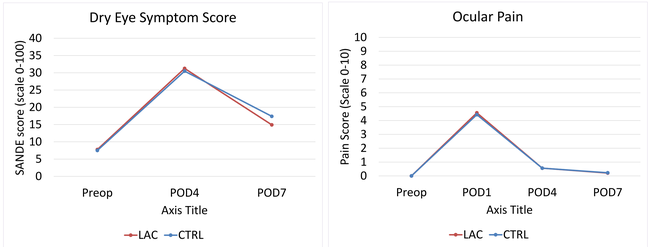

Figure 3. Dry Eye Symptom and Ocular Pain in the early postoperative period.

- Using Symptom Assessment in Dry Eye (SANDE) questionnaire, the study found no significant difference in dry eye symptom scores between LAC and CTRL up to POD7 (p=0.259).
- Ocular pain was most apparent on POD1 among participants; however, pain scores were not significantly different between LAC and CTRL (4.6 vs. 4.4, respectively; p=0.799).

Conclusions

Although eyes treated with Lacripep appeared to have smaller epithelial defects and slightly faster healing rates than placebo-treated eyes, interim analysis did not find any statistically significant differences in early outcomes. These preliminary findings suggest Lacripep may support early recovery. Continued enrollment and follow up will further evaluate potential therapeutic effect.

References

1. Wang W, Despanie J, Shi P, Edman-Woolcott MC, Lin YA, Cui H, Heur JM, Fini ME, Hamm-Alvarez SF, MacKay JA. Lacritin-mediated regeneration of the corneal epithelia by protein polymer nanoparticles. J Mater Chem B Mater Biol Med. 2014 Dec 14;2(46):8131-8141.
2. Efraim Y, Chen FYT, Cheong KN, Gaylord EA, McNamara NA, Knox SM. A synthetic tear protein resolves dry eye through promoting corneal nerve regeneration. Cell Rep. 2022 Aug 30;40(9):111307. doi: 10.1016/j.celrep.2022.111307.
3. Georgiev GA, Gh MS, Romano J, Dias Teixeira KL, Struble C, Ryan DS, Sia RK, Kitt JP, Harris JM, Hsu KL, Libby A, Odrich MG, Suárez T, McKown RL, Laurie GW. Lacritin proteoforms prevent tear film collapse and maintain epithelial homeostasis. J Biol Chem. 2021 Jan-Jun;296:100070. doi: 10.1074/jbc.RA120.015833. Epub 2020 Nov 21.
4. Feng MM, Baryla J, Liu H, Laurie GW, McKown RL, Ashki N, Bhayana D, Hutnik CM. Cytoprotective effect of lacritin on human corneal epithelial cells exposed to benzalkonium chloride in vitro Curr Eye Res. 2014 Jun;39(6):604-10. Epub 2014 Jan 8
5. Andreotti G, Lange JL, Brundage JF. The Nature, Incidence, and Impact of Eye Injuries Among US Military Personnel: Implications for Prevention. *Arch Ophthalmol.* 2001;119(11):1693–1697. doi:10.1001/archopht.119.11.1693

This work is supported by U.S. Army Medical Research Acquisition Activity Award Grant # HT9425-24-1-1092. **Disclaimer**: The views expressed in this presentation are those of the authors and do not necessarily reflect the official policy or position of Alexander T. Augusta Military Medical Center, Henry M. Jackson Foundation for the Advancement of Military Medicine, Inc., the Defense Health Agency, Department of War or U.S. Government. Discussion of any commercial products within this presentation does not create or imply any Federal/DoW endorsement.

*Government Contractors.